

Case Management of a 2 1/2 Year Old Female with a Thirty-five Degree Scoliosis and Two Hemivertebra: Outcome of Adjusting Protocols Showing a Positive Response to Chiropractic Care

Martin G. Rosen, DC, Charles L. Blum, DC

Introduction:

Searching for care that is safe and offers low levels of intervention for our children is essential in our evolving healthcare arena. One important aspect of pediatric skeletal healthcare involves the awareness and treatment of scoliosis. Adolescent idiopathic scoliosis (AIS) remains the most common deforming orthopedic condition in children [1,2]. “Increasingly, both adults and children are seeking complementary and alternative therapy, including chiropractic treatment, for a wide variety of health concerns [3].” Estimates of prevalence of mild curvature, those varying from five to twenty degrees, is thought to be between 1 to 3% of adolescents with a male to female ratio of 1:2 [4] In moderate to severe curves requiring medical management, the prevalence varies between .03 and .09% [5-7], with a male to female ratio of 1:7 [8].

Idiopathic “congenital scoliosis is the result of osseous malformations of the spine. The process of formation of the spine is extremely complex. The vertebral formation process results in either a failure of formation of part of a vertebra (hemivertebra), failure of segmentation of a vertebra (two vertebra stuck together on one side or a unilateral bar), or some combination of the two. The result is essentially a growth disturbance of the spine that produces a curvature. No two cases of congenital scoliosis are the same, and each pattern requires careful assessment to determine the risk that a serious curve will occur and need treatment. [9].”

AIS is “present in 2 to 4 percent of children between 10 and 16 years of age. It is defined as a lateral curvature of the spine greater than 10 degrees accompanied by vertebral rotation. It is thought to be a multigene dominant condition with variable phenotypic expression. Scoliosis can be identified by the Adam's forward bend test during physical examination. Severe pain, a left thoracic curve or an abnormal neurologic examination are red flags that point to a secondary cause for spinal deformity. Specialty consultation and magnetic resonance imaging are needed if red flags are present. Of adolescents diagnosed with scoliosis, only 10 percent have curves that progress and require medical intervention. The main risk factors for curve progression are a large curve magnitude, skeletal immaturity and female gender [10].”

The risk of undergoing surgery for scoliosis initially estimated to be 5% is according to the latest evidence, the rate of complications is far beyond that rate. Possible complications may be inflammation of the soft tissue or deep inflammatory processes, breathing impairments, bleeding and nerve injuries. As early as five years after surgery another 5% of patients require reoperation and today it is not yet clear what to expect from spine surgery in the long-term [11-3]. “Taking into account that signs and symptoms of spinal deformity cannot be changed by surgical intervention, surgery

remains primarily a cosmetic indication, only especially in patients with adolescent idiopathic scoliosis (AIS), the most common form of scoliosis never exceeding 80° [11-3].” Unfortunately the cosmetic effects of surgery are not necessarily stable.

This article will discuss the application of sacro occipital technique (SOT) procedures on a 2 1/2 year-old female with scoliosis and two hemivertebra and the positive results obtained through her chiropractic care. Aside from subjective patient response to treatment, improvement in clinical findings and function, Moire studies were performed to attempt to assess clinical changes from an objective standpoint. While not conclusive Moire studies have been found helpful and attained some validity in assessing changes in scoliotic patterns [14,15].

Case Presentation:

During a routine physical examination at age 6 months her pediatrician noted a curvature in her spine. An ultrasound was ordered and a scoliosis and thoracic kyphosis caused by two congenital hemivertebra was detected. On December 10, 1998 the first X-ray study was performed to monitor the scoliosis. Due to the degree of the scoliosis an MRI study was ordered on January 14, 1999 and measurements were made. A Moire study was performed on December 12, 1999. The degree of the thoracic curve was measured at thirty-five degrees. A follow up Moire study was done on December 9, 2000 and due to the progression of the scoliosis an orthopedic consult was made and he suggested that the patient undergo a surgical fusion of the involved vertebra to stabilize the scoliosis. The surgery was scheduled for April 2001

On March 9, 2001, the patient presented at my office with her mother for examination. Her mother a patient of mine contacted my office to inquire if there were any other less invasive alternatives. We suggested she bring her daughter in for an evaluation since studies have found chiropractic care successful in reducing and stabilizing scoliosis in children. The patient’s previous history was insignificant. Her prenatal, birth, and postnatal life was within normal limits. She showed no signs of developmental abnormalities except for the scoliosis and two hemivertebra previously mentioned.

Methods/Intervention:

On her initial visit on March 9, 2001 the patient underwent a complete chiropractic evaluation. Standard chiropractic evaluation procedures were used as well as specific SOT protocols [16,17]. The evaluation revealed: a right thoracic scoliosis with an accompanying thoracic kyphosis and lumbar lordosis, a right short leg in the prone and supine position, restriction in left cervical rotation, and left psoas contraction, a positive arm fossa test [18] on the right upper fossa, lateral sway of ¾ inch when standing, a posterior sacral base was noted on the left side, palpatory tenderness at T10, T4, and C2, and a positive Adams Test.

Cranial evaluation [19] revealed: a slightly posterior positioned TMJ bilaterally, a high narrow palate with medial ridging, a restriction in sphenoid motion on the left and an occipital restriction on the left.

The patient was put on a six-week intensive care program beginning March 14, 2001 to address her subluxation pattern, stabilize her Category II [20,21] complex (sacroiliac joint hypermobility and its effect on the whole body kinematic chain) and correct the cranial bone and meningeal imbalance. Her initial visit frequency was 2 visits per week for the first 6 weeks. The surgery was still scheduled for April 2001.

Results:

Six weeks after her initial chiropractic adjustment the patient was re-examined by the orthopedic surgeon prior to performing his surgical intervention and fusion. His evaluation and follow up Moire study on April 26, 2001 revealed a significant reduction in the scoliosis. Surgery was postponed and the orthopedic surgeon put the patient on a program of follow up Moire studies every six months through November 2002 to monitor the scoliosis.

Throughout the patient's care SOT evaluation and adjusting procedures were used. Applications of SOT blocking procedures and standard SOT adjustment protocols as well as reduced force cavitation adjustments were used to make the corrections.

Adjustments over the first three weeks included Category II blocking procedure [20,21] (supine pelvic wedges used to reduce pelvic torsion and joint laxity) for a right pelvic hypermobility subluxation, correct of a left psoas contraction through SOT psoas correction techniques, reduction of thoracic inferiority subluxations as determined by trapezius fiber analysis, cervical spine corrections determined by cervical stairstep indicators including C5, C2 and atlas, reduction of occipital fiber [22] line 2 rotational subluxations at T3 and T4 and cranial adjustments to the occiput and maxilla.

After the first three weeks of care Category II stabilization had been achieved and further adjustments were made using the necessary SOT indicators to continue to reduce the presenting compensatory subluxation complex and uncover an SOT Category I (anterior sacroiliac joint fixation leading to reduced sacral nutation and CSF circulation). Over the next three weeks specific reduced force adjustments were made to the right ilium and sacrum to restore normal pelvic balance. Further thoracic and cervical adjustments were made following previously stated protocols and continued cranial corrections were applied adding corrective procedures designed to reduce the hard palate dysfunction.

Discussion:

Objective findings and continued orthopedic evaluations using the Moire system of scoliosis tracking continued to show marked improvement in the patient's scoliosis. She

maintained her chiropractic care and continued on a maintenance level and continuing to see the orthopedic surgeon to monitor her scoliosis every 6 months. As of November 2002 the patient's scoliosis, kyphosis and lordosis had been drastically reduced, all her functional levels are completely normal and she was no longer a candidate for invasive surgical fusion. Since continued improvement was evident the Moire study program was stretched out to and once a year in 2003 and 2004. Her last Moire study performed on May 6, 2004 (figure #1) showed almost complete resolution of her scoliosis, kyphosis and lordosis.

Though direct clinical evidence is not conclusive from one case study it is important to note that in this particular case the patient made no other alterations in her lifestyle or clinical situation besides the addition of chiropractic care to afford such a positive outcome. Correlation of clinical findings directly supported the reduction of the patient's subluxation complex and scoliosis in this case as evident by the changed biomechanical and structural parameters, per radiological and Moire studies. Even with the additional complication of two congenital hemivertebra this patient's scoliosis was drastically reduced through consistent chiropractic care using the SOT adjusting protocols and procedures.

Chiropractic care for pediatric patients with scoliosis [23] has been discussed in the literature and in one case report it was found that utilizing Pierce chiropractic technique for a 7-year-old female patient diagnosed with idiopathic scoliosis that "along with improvement of subjective complaints, the post AP lumbopelvic radiograph showed a 62% improvement in Cobb angle after just one month of care [24]."

While there have not been many studies investigating SOT treatment of scoliosis one study discussed care of a adult patient with scoliosis who was successfully treated with a combination of SOT chiropractic care and Pilates exercise therapy [25]. With the long-term risk benefit ratios of surgical intervention on children, conservative options are both necessary and reasonable to consider. Preliminary studies are being performed to investigate how chiropractors and orthopedic surgeons can work together to facilitate improve and safer outcomes for children with scoliosis [3]. Hopefully this will lead to improved outcomes with less risk or improved outcomes from surgical interventions since the children could be helped with improved symmetrical function by the pre and post surgical inclusion of chiropractic care.

Conclusion:

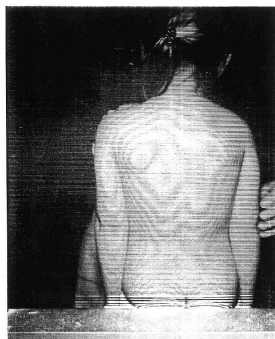
Since conservative chiropractic care in this case offered less risk to the patient, was more cost effective, and offered significant benefit it would appear that further study into the efficacy of chiropractic care in the treatment of childhood scoliosis would be prudent, especially before surgical intervention is considered. Fusion surgery for scoliosis is permanent and irreversible in nature and if conservative chiropractic care can be offered without any serious risk to the patient's health then chiropractic care should be explored in the subset of patient that responds to care. During those periods of time when the

medical physician is only monitoring the patient or preparing for possible surgical intervention, this would provide the optimal opportunity for a trial period of conservative chiropractic care.

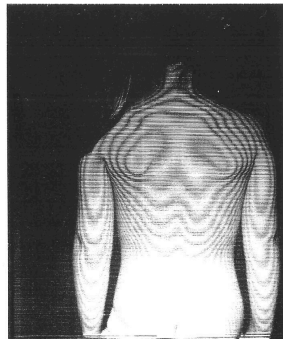
References:

1. Weiss H.F. Rehabilitation of adolescent patients with scoliosis – What do we know? A review of the literature. *Pediatric Rehabilitation*. 2003;6(3):183–194.
2. Weiss HR, Goodall D. The treatment of adolescent idiopathic scoliosis (AIS) according to present evidence. A systematic review. *European Journal of Physical and Rehabilitation Medicine*. 2008;44(2):177–93.
3. Rowe DE, Feise RJ, Crowther ER, Grod JP, Menke JM, Goldsmith CH, Stoline MR, Souza TA, Kambach B. Chiropractic manipulation in adolescent idiopathic scoliosis: a pilot study. *Chiropr Osteopat*. 2006 Aug 21;14:15.
4. Leaver J, Alvik A, Warren M: Prescriptive screening for adolescent idiopathic scoliosis. *Int J Epidemiol* 1982 , 11:101-111.
5. Brooks H, Azen S, Gerberg E, Chan L: Scoliosis: a prospective epidemiological study. *J Bone Joint Surg* 1975 , 57A:968-972.
6. Drennan J, Campbell J, Ridge H: Denver: a metropolitan public school scoliosis survey. *Pediatrics* 1977 , 60:193-196.
7. Robitaille Y, Villavicencio-Pereda C, Gurr J: Adolescent idiopathic scoliosis: epidemiology and treatment outcome in a large cohort of children six years after screening. *Int J Epidemiol* 1984 , 13:319-323.
8. Morais T, Bernier M, Turcotte F: Age and sex-specific prevalence of scoliosis and the value of school screening programs. *Am J Public health* 1985 , 75:1377-1380.
9. Jahn WT, Cupon LN. Scoliosis: What every chiropractic orthopedist needs to know [special supplement]. *eJ Acad Chiropr Orthoped*. 2007 Jun;4(Suppl):1-24.
10. Reamy BV, Slakey JB. Adolescent idiopathic scoliosis: review and current concepts. *Am Fam Physician*. 2001 Jul 1;64(1):111-6.
11. Hawes MC, O'Brien JP. A century of spine surgery: what can patients expect? *Disability and Rehabilitation*. 2008;30(10):808–17.
12. Hawes M. Impact of spine surgery on signs and symptoms of spinal deformity. *Pediatric Rehabilitation*. 2006;9(4):318–39.

13. Weiss HR, Goodall D (2008). "Rate of complications in scoliosis surgery - a systematic review of the Pub Med literature". *Scoliosis* 3: 9.
[<http://www.ncbi.nlm.nih.gov/pmc/articles/PMC2525632/>]
14. Pearsall DJ, Reid JG, Hedden DM. Comparison of three noninvasive methods for measuring scoliosis. *Phys Ther.* 1992 Sep;72(9):648-57.
15. East ADG, Kwan W. Application and Validity of Moire Topography in the Screening of Scoliosis. *Eur J Chiropr.* 1985 Jun;33(2):108-130.
16. Getzoff, H, "Sacro Occipital Technique Categories: a System Method of Chiropractic", *Chiropractic Technique*, May 1999; 11(2): 62-5.
17. Cooperstein R, Sacro Occipital Technique *Chiropractic Technique* , Aug 1996; 8(3): 125-31.
18. Hestøek L, Leboeuf-Yde C, Are chiropractic tests for the lumbo-pelvic spine reliable and valid? A systematic critical literature review, *Journal of Manipulative and Physiological Therapeutics* May 2000;23:258–75.
19. Pederick FO. A Kaminski-type evaluation of cranial adjusting. *Chiropractic Technique.* Feb 1997;9(1): 1-15.
20. Blum CL, Letter to the Editor: Sacroiliac Dysfunction and SOT - Response to the Nov. JACA Online Focus article on sacroiliac joint dysfunction. *Journal of the American Chiropractic Association.* Dec 2006: 20-1.
21. Hochman JJ, The Effect of Sacro Occipital Technique Category II Blocking on Spinal Ranges of Motion: A Case Series *Journal of Manipulative and Physiological Therapeutics*, Nov 2005;28(9): 719-23.
22. Mootz R, Jameson S, Menke M, Inter and Intra-Rater Reliability of Occipital Fiber Palpation *Proceedings of the Fifth Annual Conservative Health Science Research Conference* Oct 1986: 37-9.
23. Robert J, Perret C. Differentiating progressive from non-progressive adolescent idiopathic scoliosis. *Eur J Chiropr.* 2002 ;49(1):13-7.
24. Jaszewski E, Sorbara A. Improvement in a child with scoliosis, migraines, attention deficit disorder and vertebral subluxations utilizing the Pierce chiropractic technique. *J Pediatr Matern & Fam Health - Chiropr.* 2010 Spr;2010(2): 30-34.
25. Blum CL. Chiropractic and pilates therapy for the treatment of adult scoliosis. *J Manipulative Physiol Ther.* 2002 May;25(4):E3.



December 9, 2000



May 6, 2004

Figure 1. Pre and post Moire Studies